

## Original Article

# Histopathological Effects of Exposure of Formaldehyde on Nasal Cavity of Albino Rats

**Monika Gupta**

*Assistant Professor, Department of Anatomy, RUHS College of Medical Sciences and RDBP Jaipuria Hospital, Jaipur, Rajasthan, India*

### ABSTRACT

**Introduction:** Formaldehyde is a colourless, inflammable, and strong smelling chemical used extensively in various industries as well as in medical laboratories. People working in industry producing formaldehyde or formaldehyde containing products are exposed to high concentration of formaldehyde. The aim of the present study was to observe the effects of exposure of formaldehyde on nasal cavity of albino rats.

**Methodology:** In the present study, sixty albino rats were exposed to 10 ppm of formaldehyde for 9, 18, and 36 days. After completion of every inhalation exposure period, rats were sacrificed and their tissue samples were taken from nasal mucosa in order to be processed and stained with haematoxylin and eosin for light microscopic study.

**Results:** The histopathology showed cell proliferative changes in the epithelium of nasal cavity. These changes increased with the increase in duration of exposure.

**Conclusion:** Acute and sub chronic formaldehyde exposure shows correlation between cell proliferation and nasal carcinogenesis. Therefore, proper precautionary measures should be taken while handling chemical toxin like formaldehyde.

### INTRODUCTION

Formaldehyde is an inflammable, colourless, reactive, and readily polymerized gas at room temperature and pressure.<sup>1</sup> It is manufactured worldwide on a large scale by the method of catalytic, vapour-phase oxidation of methanol<sup>2</sup> and is a common air pollutant.<sup>3,4</sup> It is commonly used as an industrial fungicide, germicide, disinfectant, and also as a preservative in mortuaries and medical laboratories.<sup>2</sup> People working in industry producing formaldehyde or formaldehyde containing products are exposed to high concentration of formaldehyde where the exposure occurs primarily by inhaling formaldehyde

vapours from the air.<sup>1</sup>

Several long-term formaldehyde inhalation exposure studies done on rats and mice in the past have shown respiratory symptoms in them as well as histological changes in respiratory and olfactory epithelium. The respiratory symptoms in rats and mice include allergic inflammatory reactions such as rhinitis, bronchial hyperresponsiveness, and airway inflammation.<sup>5</sup> The histological changes include lesions like epithelial dysplasia and squamous metaplasia when respiratory route was chosen.<sup>6,7,8</sup> As the effects of chemical toxin like formaldehyde on respiratory system are poorly understood, the present study was conducted to study short-term effect of formaldehyde exposure on nasal mucosa of rats. Histopathological effects of formaldehyde on nasal cavity of albino rats have been studied in the study.

### METHODS

A total of sixty albino rats of charles - foster strain (32 male and 28 female) were used as experimental animals in the present study. The study was conducted in Himalayan Institute of Medical Sciences, Dehradun. The animals were obtained from central animal house of the same institute. Necessary animal ethical approval was taken prior to commencement of the study. The stocks of rats were nutritionally healthy and free from any disease or disability and were fed standard balanced diet. Sixty albino rats were divided into four groups (n=15 in each group). Group A for control which was non-exposure group while experimental groups B, C, and D were exposed to 10 ppm formaldehyde vapour for 9, 18, and 36 days, respectively.

After the completion of every inhalation exposure period, animals of that group were sacrificed by decapitation after ether inhalation to procure tissues of nasal mucosa. The head of animals were immersed into formic acid for

decalcification, 3-5 mm thick tissue slices were taken and processed for sectioning and staining with haematoxylin and eosin. The slide examination under light microscope was done on 25 randomly selected areas of epithelium in all groups. Vertical thickness of epithelium was measured as a distance from basement membrane to ciliary apex and the increase in thickness was termed as hypertrophy. Number of cells per 10µm of epithelium was counted and the increase in the number of cells per 10µm of epithelium was termed as hyperplasia. The measurements were done with the help of eyepiece micrometer. Results were statistically evaluated using students t-test.

**RESULTS**

The microscopic examination of the animals of control and experimental groups was done. The nasal mucosa of control group A was found normal with no histopathological changes, whereas the experimental groups (B, C, and D) animals presented a wide variety of epithelial changes in nasal mucosa. All the histopathological findings observed in the nasal epithelium of experimental groups were thoroughly compared with the nasal epithelium of control group A (Figure 1 and 2). The study was done on 25 randomly selected areas of epithelium in all groups (control and three different formalin exposure groups). The increase in thickness of nasal epithelium (epithelial hypertrophy) was statistically significant in all exposure groups (group B, C, and D) when compared with control group A ( $p \leq 0.05$ ) (Table 1). The increase in mean number of cells per 10µm length of epithelium (epithelial hyperplasia) was statistically significant in all exposure groups (group B, C, and D) when compared individually with control group A ( $p \leq 0.05$ ).

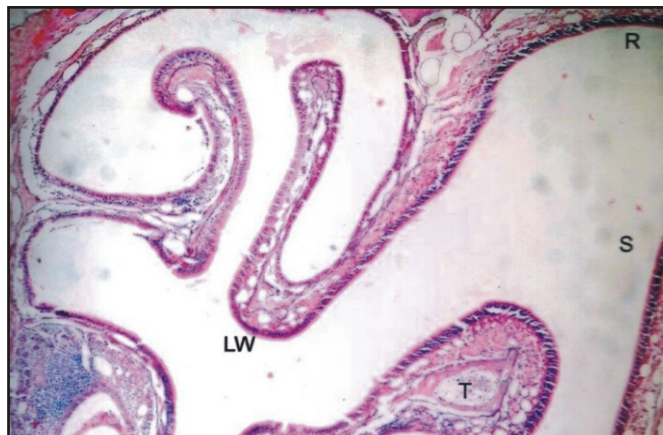
**Table 1: Mean thickness of nasal epithelium in various formalin exposure groups**

Groups	Thickness of epithelium (µm)
A	7.00±0.89
B	10.16±2.23*
C	10.68±1.99*
D	11.92±2.09*

\*  $p \leq 0.05$

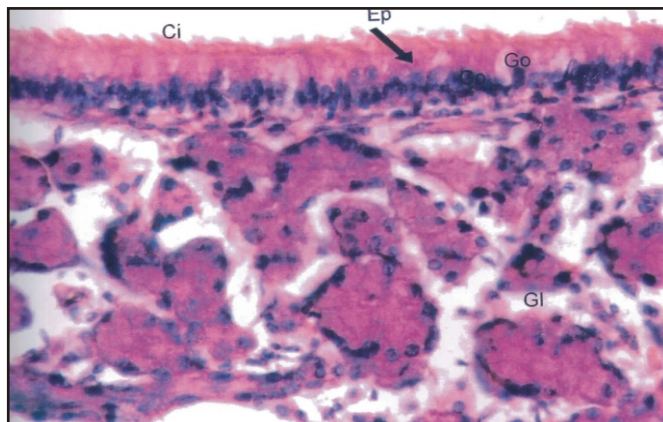
Alongwith all these changes, dilated and congested blood vessels were seen in all exposure groups. Total epithelial detachment and focal ulceration was also observed primarily in group C and group D. These changes were extensively seen in group D (Figure 3). Hypertrophy of

submucosal glands was found in group C and D. Cytoplasmic vacuolations and intracellular edema was noticed in the nasal cavity of all exposure groups but these findings were most widespread in group D (Figure 4). Group D rats showed ill-defined nuclear membrane, nuclear atypia, and pyknotic changes in nasal epithelium.



**Figure 1: H and E stained panoramic view of nasal cavity of group A (10x).**

S- nasal septum; R- roof; LW- lateral wall; T-turbinate of nasal cavity.



**Figure 2: H and E stained sectional view of nasal cavity of group A (40x).**

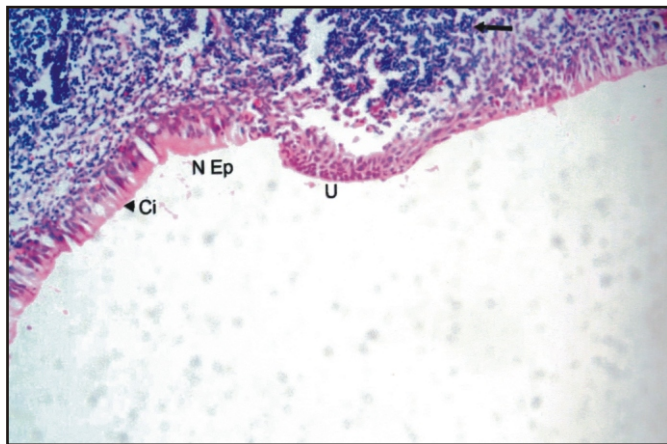
Pseudostratified ciliated columnar epithelium having few goblet cells.

**DISCUSSION**

Formaldehyde is a well-known respiratory irritant. Formaldehyde induced respiratory effects are more prevalent in upper respiratory tract than lower respiratory tract.<sup>9</sup> Formaldehyde present in air is primarily absorbed in upper respiratory tract and high concentration of this chemical is found in the nasal mucosa of exposed rats.<sup>10</sup> Studies have been conducted on long-term effects of 10 ppm of formaldehyde exposure on respiratory epithelium of rats. It has been reported that formaldehyde can

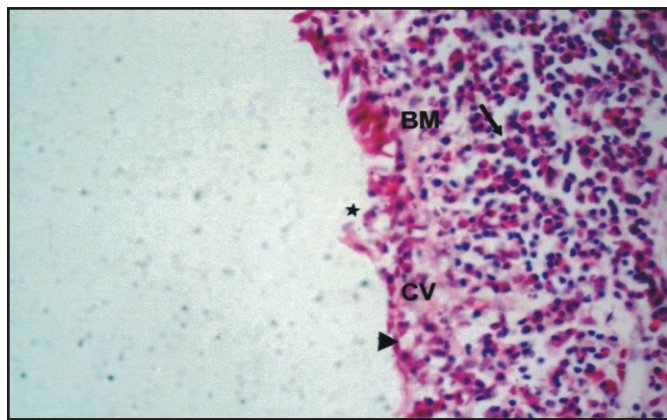


cause squamous cell carcinoma in nasal cavity.<sup>6</sup>



**Figure 3: H and E stained sectional view of nasal cavity of group D (40x).**

Focal ulceration (U) with inflammatory infiltrate (arrow) in comparison with normal respiratory epithelium (N Ep).



**Figure 4: H and E stained sectional view of nasal cavity of group D (40x).**

Loss of cilia (arrow head), cytoplasmic vacuolation (CV), loss of basement membrane (BM), epithelial erosion (\*), inflammatory infiltrate in lamina propria and sub mucosa (arrow).

In the present study, formaldehyde was used at 10 ppm concentration. It resulted in proliferative changes in nasal epithelium of albino rats in the form of epithelial hypertrophy and epithelial hyperplasia. On the contrary, Woutersen RA et al<sup>11</sup> described that 10 ppm of formaldehyde exposure to undamaged rat nasal epithelium for 28 months do not produce squamous cell carcinoma and epithelial changes were only hyperplastic, inflammatory, and degenerative types. Likewise, Feron et al<sup>12</sup> exposed rats to 10 ppm of formaldehyde for eight weeks and observed focal hyperplasia and focal squamous metaplasia of respiratory epithelium. Formaldehyde was cytotoxic at concentration  $\geq 6$ ppm and increase rate of surface epithelial cell proliferation in rats as studied

previously.<sup>13</sup> Similar effects were also observed in monkeys by Monticello TM et al<sup>14</sup> and in xenotransplant nasal epithelium by Klein-szanto AJP et al.<sup>15</sup>

In the present study, statistically significant cell proliferation in the form of epithelial hypertrophy and hyperplasia over control animals was evident even after exposure of formaldehyde for a short exposure period i.e. only for nine days. A study in monkeys reported increase in cell proliferation after one week.<sup>14</sup>

Another study on rats<sup>16</sup> documented that after nine days cell proliferation in the form of labelling index (LI) returned to control levels in six ppm group while LI remained elevated in 15 ppm group. In a previous study<sup>15</sup> on xenotransplanted human nasal epithelium in rats, significant hyperplasia was reported to be present after two weeks of 0.5 and 1 mg of formaldehyde exposure, after eight weeks it returned to normal in 0.5 mg group while in 1 mg group it remained significantly elevated. In contrast to these findings, our study showed cell proliferation remains elevated in all exposure groups as compared to control group i.e. after 9, 18 and 36 days of formaldehyde exposures. Likewise, Monticello et al<sup>14</sup> also found that cell proliferation continue to be elevated in both one and six week exposure groups in monkeys.

Focal hyperplasia in respiratory epithelium of rats was reported after four and eight weeks of exposure.<sup>9</sup> Squamous metaplasia was also found<sup>12,14</sup> but not visible in the present study. Present study clearly indicates that increase in cell proliferation occurs even after short-term formaldehyde exposure which was also seen in similar studies done on rats, monkeys, and human nasal epithelium.<sup>14,15,16</sup> However, a difference in the pattern of cellular proliferation with the duration of exposure was observed in various similar investigations done in different species such as rats, monkeys, and human. The difference in the findings may be attributed to different tissue susceptibility, difference in nasal airflow pattern, or some other not well known factors.<sup>14</sup> Formaldehyde is an upper respiratory tract irritant which is almost entirely deposited in the nasal cavity of rodents.<sup>9,13</sup> Grisham JW et al<sup>17</sup> stated that malignancies are common in tissue induced to proliferate rapidly by provoking stimuli. Also, there is a direct relation between formaldehyde induced carcinogenesis and increase in cell proliferation resulting from formaldehyde induced cytotoxicity.<sup>14</sup>

As the study was limited up to a period of 36 days, only

cell proliferative changes were observed in the nasal mucosa. Altered cell proliferation has been considered a sensitive indicator of toxicity and found essential for both initiation and promotion of carcinogenesis. By prolonging the period of formaldehyde exposure on rats, carcinomatous changes may be visible in the nasal epithelium.

### CONCLUSION

In the present study, increase in cell proliferation increases with duration of exposure which may be due to time-dependent nature of formaldehyde toxicity. Thus, this short-term formaldehyde inhalation exposure study indicates that studies must be undertaken to establish a correlation between formaldehyde induced cell proliferation and nasal carcinogenesis.

**Acknowledgement:** Sincere thanks to my teachers Dr Sohail A Perwaiz and Dr RK Rohatgi for their invaluable suggestions and support in completing this study.

### REFERENCES

1. Environment health criteria 89: formaldehyde (US). Formaldehyde health and safety guide no. 57. Geneva; WHO: 1991.
2. IARC Monograph Programme on the Evaluation of Carcinogenic Risk to Human vol. 88; IARC; 2004.
3. Salthammer T. Formaldehyde in the ambient atmosphere: from an indoor pollutant to an outdoor pollutant? *Angew Chem Int Ed Engl* 2013; 52(12):3320-27.
4. Juanjuan Zhang, Jihong Dai, Li yan, Wenlong Fu, Jing yi. Air pollutants, climate, and the prevalence of paediatric asthma in urban areas of china. *Bio Med Res Int* 2016; 2016:8.
5. Luanluan Li, Li Nua, Yafang Ne, Yixiao Bao. Differential effects of formaldehyde exposure on airway inflammation and bronchial hyper-responsiveness in BALB/c and C57BL/6 mice. *PLoS one*. 2017; 12(6):e0179231.
6. Kern WD, Pavkov KL, Donofrio DJ, Gralla EJ and Swenberg JA. Carcinogenic effect of formaldehyde in rat and mice after long-term inhalation exposure. *Cancer Res* 1983; 43:4382-92.
7. Recio L, Sisk S, Pluta L, Bermudez E, Gross EA, Chen Z, et al. P<sup>53</sup> mutation in formaldehyde induced nasal squamous cell carcinoma in rats. *Cancer Res* 1992; 52: 6113-16.
8. Morgan KT, Jiang XZ, Starr TB, Kern WD. More precise localization of nasal tumor associated with chronic exposure of F-344 rats to formaldehyde gas. *Toxicol Appl Pharmacol* 1986; 82: 264-72.
9. Mathur N and Rastogi SK. Respiratory effects due to occupational exposure to formaldehyde: Systemic review with meta analysis. *Indian J Occup Environ Med* 2007; 11(1): 26-31.
10. Heck HdA, Chin TY, Schmitz MC. Distribution of [<sup>14</sup>C] formaldehyde in rats after inhalation exposure. In: Gibson york: hemisphere publishing corp; 1983 : 26-34.
11. Woutersen RA, Van Garderen Hoetmer A, Brnijntjes JP, Zwart A, Feron VJ. Nasal tumours in rats after severe injury to the nasal mucosa and prolonged exposure to 10 ppm formaldehyde. *J Appl Toxicol* 1989 ; 9 (pt1): 39-46.
12. Feron VJ Bruyntjes JP, Wouterson RA, Immel HR, Appelman LM. Nasal tumors in rats after short-term exposure to a cytotoxic concentration of formaldehyde. *Cancer Lett* 1988; 39:101-20.
13. Chang JCF, Gross EA, Swenberg JA, Barrow CS. Nasal cavity deposition, histopathology and cell proliferation after single or repeated formalde-hyde exposures in B6C3FI mice and F-334 rats. *Toxicol Appl Pharmacol* 1983; 68:161-76.
14. Monticello TM, Morgan KT, Everitt JI, Popp JA. Effect of formaldehyde gas on the respiratory tract of rhesus monkeys. *Am J Pathol* 1989; 134 (pt3):515-27.
15. Klein-szanto AJP, Ura H, Resau J. Formaldehyde-induced lesion of xenotransplanted nasal respiratory epithelium. *Toxicol Pathol* 1989; 17:33-37.
16. Swenberg JA, Gross EA, Randall HW: Localization and quantitation of cell proliferation following exposure to nasal irritants. *Toxicology of Nasal passage*. In: Hemisphere publishing corp; 1986:291-98.
17. Grisham JW, Kaufmann WK, Kaufmann DG: The cell cycle and chemical carcinogenesis. *Surv Synth Path Res* 1983; 1:49-66.

### Corresponding Author

Dr Monika Gupta, D-222, Malviya Nagar, Jaipur, Rajasthan, India.

email: [drmonikagupta2016@gmail.com](mailto:drmonikagupta2016@gmail.com)